



## Embolizations of the hepatic tumors - two-year single center experience

### Embolizacije tumora jetre – dvogodišnje iskustvo jednog centra

Dariusz Janczak\*, Dorota Zielińska<sup>†</sup>, Jerzy Pawelczyk<sup>†</sup>, Tadeusz Dorobisz\*,  
Jerzy Garcarek<sup>‡</sup>, Dariusz Patrzalek\*, Mariusz Chabowski<sup>\*§</sup>

\*Wrocław Medical University, Faculty of Postgraduate Medical Training, Department of Vascular, General and Transplantation Surgery, Wrocław, Poland; <sup>†</sup>4th Military Clinical Hospital in Wrocław, Department of Surgery, Wrocław, Poland; <sup>‡</sup>Wrocław Medical University, Procedural Radiology and Neuroradiology, Department of General Radiology, Wrocław, Poland; <sup>§</sup> Wrocław Medical University, Faculty of Health Science, Division of Nursing in Surgical Procedures, Wrocław, Poland

#### Abstract

**Background/Aim.** Transcatheter arterial chemoembolization (TACE) and portal vein embolizations (PVE) are established methods of treatment of patients with hepatic tumors. The aim of the study was to present our experience in the treatment of liver tumors with embolization as a preliminary treatment for surgery or a part of palliative treatment. **Methods.** The analysis included 29 patients who had undergone 34 embolizations. **Results.** TACE was performed in 26 cases with hemangiomas in the unfavorable location, or mass effect and inoperable malignant tumors both primary and metastatic. PVE was performed in 8 cases with primary liver tumors and colon liver metastases. All included patients presented inoperable hepatic tumors. TACE was carried out in the patients with hepatocellular carcinoma (n = 1), cholangiocarcinoma (n = 1), metastatic tumor (n = 8), and hemangioma (n = 16), while PVE in the patients with cholangiocarcinoma (n = 2), metastatic tumor (n = 5) and neuroendocrine tumor (n = 1). The embolization was followed by surgery in the 5 PVE patients and 6 TACE patients. The postembolization syndrome was observed in 7 subjects. Death due to cancer progression occurred in the 4 PVE patients and 7 TACE patients. One patient died during TACE due to hemorrhagic shock. **Conclusions.** Right PVE and selective TACE are efficient for preliminary preparation of patients with healthy hepatic parenchyma for major liver resections, but the patients with liver cirrhosis require careful assessment. In the patients with hemangioma, embolization allows to avoid surgical treatment by reducing the lesion mass, or the extent of hepatic resection. The preliminary results of arterial embolizations with bleomycin, leading to tumor reduction in cases of giant liver hemangiomas are promising.

#### Key words:

liver neoplasms; embolization, therapeutic; digestive system surgical procedures; bleomycin.

#### Apstrakt

**Uvod/Cilj.** Transkateterska arterijska hemoembolizacija (TAHE) i embolizacija portne vene (EPV) su ustanovljene metode u lečenju tumora jetre. Cilj studije bilo je prikazivanje našeg iskustva u lečenju tumora jetre, bilo kao preliminarno lečenje pre hirurškog zahvata, bilo kao deo palijativnog lečenja. **Metode.** Analiza je uključila 29 bolesnika kojima su učinjene 34 embolizacije. **Rezultati.** TAHE je učinjena kod 26 bolesnika sa hemangiomima na nepovoljnoj lokalizaciji ili kao redukcija kod inoperabilnih malignih tumora, bilo primarnih ili metastatskih. EPV je učinjena kod osam bolesnika sa primarnim tumorima jetre i metastazama u jetri iz kolona. Kod svih su tumori jetre bili inoperabilni. TAHE je učinjena kod jednog bolesnika sa hepatocelularnim karcinomom, jednog sa holangiokarcinomom, kod osam sa metastatskim tumorom, i kod 16 bolesnika sa hemangiomom. EPV je učinjena kod dva bolesnika sa holangiokarcinomom, pet bolesnika sa metastatskim tumorom i jednog sa neuroendokrinim tumorom. Kod pet bolesnika EPV embolizacija prethodila je hirurškom tretmanu, a TAHE kod šest bolesnika. Postembolizacijski sindrom je praćen kod sedam bolesnika. Smrt zbog progresije karcinoma nastupila je kod četiri EPV bolesnika i 7 TAHE bolesnika. Jedan bolesnik umro je tokom TAHE zbog hemoragijskog šoka. **Zaključak.** Uspešna desna PVE i selektivna TAHE su efikasne kod preliminarne pripreme bolesnika sa zdravim parenhimom jetre za opsežne resekcije jetre, ali bolesnici sa cirozom jetre zahtevaju pažljivu procenu. Kod bolesnika sa hemangiomom, embolizacija omogućava izbegavanje hirurškog zahvata zbog hirurške redukcije tumorske mase ili smanjuje opsežnost hirurškog zahvata. Preliminarni rezultati arterijske embolizacije bleomicinom pokazuju obećavajuće rezultate kod gigantskih hemangima jetre.

#### Ključne reči:

jetra, neoplazme; embolizacija, terapijska; hirurgija digestivnog sistema; procedure; bleomicin.

## Introduction

Embolization is a method used in the treatment of liver tumors as an alternative to surgical treatment as well as for a preparation for major liver resections<sup>1</sup>. In the 4th Military Clinical Hospital in Wrocław, embolizations with the closure of both the hepatic arteries and portal vein branches have been performed since July 2013. This procedure is reserved for the patients who do not qualify for surgery due to a large tumor, hazardous (particularly parahilar) location, or poor overall health status while meeting conditions for embolization. By blocking the tumor blood supply, arterial embolization selectively cuts off the supply of nutrients and oxygen to the tumor tissues.

Embolization procedure consists of introducing a fine catheter along the arteries into the close vicinity of the tumor and delivering a substance that causes the closure of the arterial vessel. In contrast to healthy liver parenchyma, the tumor cells receive the nutrients from the hepatic artery rather than from the hepatic vein vessels; thus, transcatheter arterial chemoembolization (TACE) was introduced to administer a chemotherapeutic agent followed by the vessel closure and radioembolization. The most frequent radiotherapeutic agent used in TACE is yttrium-90, which, delivered in microspheres, undergoes radioactive decay to release energy by destroying the tumor cells<sup>2,3</sup>.

The portal vein embolization (PVE) is a procedure involving the transcutaneous punctures of the branches of the right (less commonly the left) branch of the portal vein followed by an introduction of the vessel-closing agent. This is aimed at blocking blood from being supplied via the portal vein into a hepatic lobe to induce secondary hypertrophy of the other hepatic lobe. This allows for the major resection procedures being performed on the initially inoperable liver tumors. Hepatic hypertrophy increases the efficacy of the part of hepatic parenchyma being left after the resection; thus, PVE is a procedure that prepares the patient for major resections and enables the remaining part of the liver to function properly. Optimum hepatic hypertrophy is achieved 2–4 weeks after the procedure in healthy hepatic parenchyma and 6–8 weeks after the procedure in liver cirrhosis of steatosis.

The aim of the study was to present the embolization as a method for a treatment of inoperable liver tumors and a part of palliative treatment in large or numerous nodular liver lesions in the patients disqualified from surgery, with lesions in parahilar location or as a preliminary treatment for surgery of large focal liver lesions within a single lobe.

## Methods

The study included 34 embolizations performed in 29 patients (14 male and 15 female patients) in the 4th Military Clinical Hospital in Wrocław, Poland between July 2013 and December 2015. The mean age of all patients was 55.5 years. At the time of the procedure, the youngest patient was a 39-years-old male patient with an extensive hemangioma within the right hepatic lobe treated with arterial embolization procedure. The oldest patient was an 83-years-old male patient

subjected to two arterial embolization procedures due to inoperable hepatic metastases of colon cancer.

Among analyzed embolizations, 26 procedures were TACE and 8 PVE. Indications for TACE included the large benign liver tumors (hemangiomas, focal nodular hyperplasias) with unfavorable, i.e., parahilar location or presenting with the mass effect as well as the large inoperable malignant tumors within the liver both primary and metastatic. TACE were also performed in the patients who were disqualified from the surgical treatment due to their overall health condition, numerous comorbidities, or the presence of other contraindications for general anesthesia. The embolizations were not performed in the patients with hepatic abscesses or cysts. TACE may be carried out periodically depending on the expected outcomes. Indications for PVE included large or numerous malignant tumours within a single hepatic lobe that, if resected without prior embolization, would lead to postoperative liver failure due to the insufficient amount of liver parenchyma being left after the surgery.

All procedures were followed in accordance with the ethical standards and with the Helsinki Declaration of 1964 and later versions. The informed consent was obtained from all the patients included in the study. The patients' medical records were analyzed retrospectively. The data were presented as means and percentages.

## Results

In the study, the liver embolizations were performed in the patients with the inoperable hepatic tumors: 16 in benign and 18 in malignant. The benign lesions included hemangiomas, while the malignant lesions included hepatocellular carcinoma (HCC) – cases secondary to post-hepatitis C virus (HCV) and post-hepatitis B virus (HBV) inflammation cirrhosis; cholangiocarcinoma (CC); neuroendocrine tumors and colon cancer metastases. Three patients had to undergo repeated embolizations due to the extent of nodular lesions. Of these, one patient underwent TACE procedure 4 times as a staged treatment of extensive hemangiomas within both liver lobes. The patient was qualified for the surgery that involved the resection of liver segments 2, 3, 4, and 5. Lipiodol, polyvinyl alcohol (PVA) and metal springs were most often used as embolization agents. In 13 cases, bleomycin was used. Cases qualified for PVE included 2 patients diagnosed with HCC, one patient with a neuroendocrine tumor and 5 patients with hepatic metastases of colon cancer.

Right PVE was performed in 8 patients; 5 of these patients were subsequently subjected to the surgical treatment (Figures 1–3), while the remaining 3 underwent the embolization procedure as part of palliative treatment. Palliative TACE was performed in 6 cancer patients. In 10 patients with hemangiomas, TACE resulted in the reduction in the lesion size allowing for the abandonment of surgical treatment. Surgical procedures were performed after TACE in 6 patients. The liver failure symptoms developed after right-sided hemihepatectomy in 2 patients with post-inflammatory cirrhosis after the HBV infection and type II diabetes (following right PVE).

Table 1

## The characteristics of the study group and the results of the treatment

Characteristics of the patients	Type of embolization	
	PVE (n = 8 cases)	TACE (n = 26 cases)
Mean age of patients (years)	63.3	47.7
Diagnosis	2 HCC, 5 metastases of colon cancer, 1 neuroendocrine tumor	1 HCC, 7 metastases of colon cancer, 1 neuroendocrine tumor metastasis, 16 hemangiomas, 1 CC
Mean duration of hospitalization (days)	5.5	4.5
Number of patients undergoing surgery	5 surgeries: 3 hemihepatectomies 1 laparotomy (biopsy) 1 laparotomy (biopsy and RTA)	6 surgeries: 4 cancer cases – laparotomy (biopsy) 2 hemangioma cases – resection procedures
Deaths (n)	4 due to cancer progression	1 perioperative 7 due to cancer progression

PVE – portal vein embolization; TACE – transcatheter arterial chemoembolization; CC – cholangiocarcinoma; HCC – hepatocellular carcinoma; RTA – radio-frequency thermoablation.

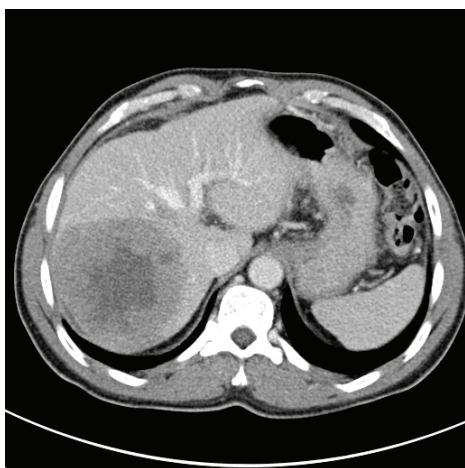


Fig. 1 – The patient with hepatocellular carcinoma before the portal vein embolization. Computed tomography scan shows a large hypodense and heterogenous tumor in the segments VII and VIII and partially in the segments V and VI of the right hepatic lobe, measuring 88 × 90 × 90 mm, with necrosis in the central part.

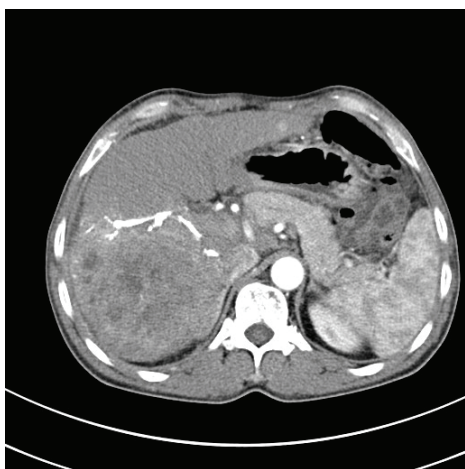


Fig. 2 – Computed tomography scan shows the reduced size of the hepatic tumor of the same patient after the procedure of portal vein embolization.

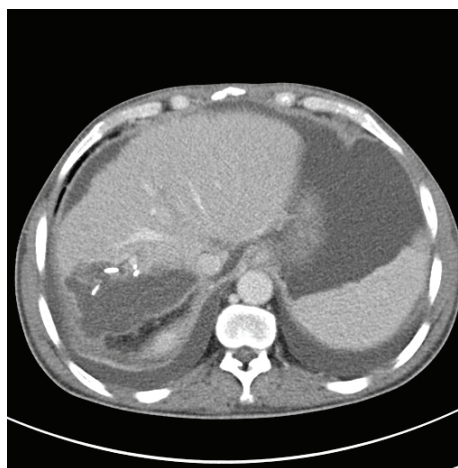


Fig. 3 – The same patient after the right hemihepatectomy. Computed tomography scan shows the irregular and encysted fluid collection in the tumor bed, measuring 80 × 52 × 42 mm, of 20 Hounsfield units (HU) density, suggesting a postoperative inflammation.

Deaths occurred in 12 patients: one was due to perioperative hemorrhagic shock and 11 were due to the progression of cancer several months after the embolization. The postembolization syndrome was observed in 7 subjects and manifested as transient abdominal pain with isolated episode of increased body temperature up to 38°C observed during the hospitalization. The symptoms resolved after administration of analgesic and antipyretic drugs. No abscesses or necrotic foci requiring surgical interventions were observed. Table 1 presents characteristics of the study group and results of the treatment.

### Discussion

In most countries, 5-year survival from liver cancer is low (below 20%) indicating that most patients are diagnosed when they are inoperable<sup>4</sup>. Additionally, primary liver and biliary cancers are very aggressive tumors which are the second leading cause of cancer death worldwide. The incidence

of those cancers decreases in Europe due to the decline of seroprevalence of hepatitis B virus (HBV) as well as targeted screening and treatment of the HCV <sup>5</sup>. In Poland, chronic HCV affects about 200,000 individuals, but very few of them are aware of the infection, and even fewer are treated <sup>6</sup>. The present study included only the inoperable liver tumors which were treated to enable surgery or as a part of palliative treatment. All 3 cases of HCC were associated with underlying hepatitis which is a risk factor for the poor prognosis.

Surgical resection is a gold standard for hepatic malignancies, but a majority of patients are diagnosed in inoperable state, thus embolization plays an important role in the treatment. The transarterial embolization is considered a palliative therapy for multifocal and large malignant tumors. The aim of this procedure is to deliver a chemotherapeutic drug and/or embolizing agent into the tumor, causing its necrosis. Data from the relevant literature indicates that better results are obtained in smaller lesions. Miraglia et al. <sup>7</sup> performed TACE in the patients with HCC and obtained complete necrosis in 68% of patients with lesion between 4.1–5.0 cm, 50% of patients with lesion between 5.1–6.0 cm, and only 13% of patients with lesions over 6 cm. In hemangioma, TACE may be used as alternative to surgery, or with the aim to reduce the tumor size prior to surgery. Sun et al. <sup>8</sup> reported a significant decrease in the tumor size from 11.24 to 7.60 cm six months after embolization. In the present study, surgery was performed in 6 (23.08%) patients who had undergone TACE. This type of embolization enabled surgery in 4 cancer patients, diminished extent of the resection by reducing the mass of hemangioma in 2 cases, and allowed to avoid surgical treatment in 14 hemangioma patients.

The aim of PVE is to induce regrowth of properly functioning liver parenchyma prior to a planned resection of a hepatic tumor. In case of malignant lesions, PVE may be combined with TACE. Disadvantage of this procedure is the delay of radical treatment increasing the tumor growth and the possibility of the lack of liver hypertrophy. The patients with primarily unresectable tumors require special approach because primary resectability of those tumors is limited mainly due to insufficient future liver remnant volume (FRLV). Risk factors such as chemotherapy, steatosis, diabetes mellitus, cholestasis and cirrhosis determine the development of the post-hepatectomy liver failure. Previous studies suggest that FRLV of above 20% is safe in healthy livers, above 30% in steatosis or during chemotherapy and above 40% in cirrhosis <sup>9</sup>. Many researchers create strategies that help to increase the FRLV pre-operatively to ensure the proper liver function after surgery. Embolization is one the methods which decrease the rate of hepatic complications. It is recommended when FRLV drops below 40% in the liver

affected by a disease. <sup>9–11</sup> Volumetry of the liver is assessed directly before and 3–4 weeks after the embolization. Obtained hypertrophy correlates with frequency of liver complications, hepatic failure, length of hospitalization and mortality <sup>12</sup>. Extended hepatectomy may result in presentation with liver failure symptoms due to reduced mass of liver which is insufficient to maintain normal liver function. Clinical manifestation of liver insufficiency after extended hepatectomy is known as small for size syndrome (SFSS). Recent studies suggest that it is determined not only by FRLV but also by the hemodynamic parameters of the hepatic circulation <sup>13–15</sup>. In the present study, 2 out of 3 subjects with HCC, hepatic cirrhosis, and diabetes presented with liver failure symptoms after hemihepatectomy, despite meeting the 40% threshold of FRLV before surgery. This indicates that further research is required in the scope of the pathogenesis of SFSS which would allow surgeons for better qualification of the patients for liver surgery.

The presence of liver metastases in the patients with colon cancer determines poor prognosis. The surgical resection improves survival, but it may be impossible in cases with large lesions. The surgical removal of colorectal liver metastases improves survival in comparison with nonsurgical treatment (5-year overall survival rate 47% vs 6%). Repeated surgery has similar survival rate to surgical removal <sup>5</sup>. The present study included 5 cases of metastases of colon cancer subjected to PVE and 7 subjected to TACE. The majority of those embolizations were given to treat liver metastases for palliative effects.

### Conclusion

The right portal vein branch or selective arterial embolization is an efficient method of preliminary preparation of patients with healthy hepatic parenchyma for major liver resections. No hepatic hypertrophy suitable for the proper functioning of parenchyma preserved after the resection was obtained in the patients with liver cirrhosis. In case of hemangiomas, the embolization allows to avoid surgical treatment by reducing the lesion mass, or to reduce the extent of resection procedures. The preliminary results of arterial embolizations with bleomycin leading to tumor reduction in cases of giant liver hemangiomas are very promising.

### Acknowledgments

This study was not funded by any grants.

### Conflict of interest

The authors declare no conflict of interest in this work.

## R E F E R E N C E S

1. Glantzounis GK, Tokidis E, Basourakos SP, Ntzani EE, Lianos GD, Pentheroudakis G. The role of portal vein embolization in the surgical management of primary hepatobiliary cancers. A systematic review. *Eur J Surg Oncol* 2017; 43(1): 32–41.
2. Guan YS, He Q, Wang MQ. Transcatheter arterial chemoembolization: History for more than 30 years. *ISRN Gastroenterol* 2012; 2012: 480650.
3. Brown DB, Geschwind JH, Soulen MC, Millward SF, Sacks D. Society of Interventional Radiology position statement on che-

- moembolization of hepatic malignancies. *J Vasc Interv Radiol* 2009; 20(7 Suppl): S317–23.
4. *Allemani C, Weir HK, Carreira H, Harewood R, Spika D, Wang XS, et al.* Global surveillance of cancer survival 1995-2009: Analysis of individual data for 25, 676, 887 patients from 279 population-based registries in 67 countries (CONCORD-2). *Lancet* 2015; 385(9972): 977–1010.
  5. *Lemke J, Cammerer G, Gansler J, Scheele J, Xu P, Sander S, et al.* Survival and Prognostic Factors of Colorectal Liver Metastases After Surgical and Nonsurgical Treatment. *Clin Colorectal Cancer* 2016; 15(4): e183–e192.
  6. *Flisiak R, Halota W, Tomasiwicz K, Kostrzewska K, Razavi HA, Gower EE.* Forecasting the disease burden of chronic hepatitis C virus in Poland. *Eur J Gastroenterol Hepatol* 2015; 27(1): 70–6.
  7. *Miraglia R, Pietrosi G, Maruzzelli L, Petridis I, Caruso S, Marrone G, et al.* Efficacy of transcatheter embolization/chemoembolization (TAE/TACE) for the treatment of single hepatocellular carcinoma. *World J Gastroenterol* 2007; 13(21): 2952–5.
  8. *Sun J, Nie C, Zhang Y, Zhou G, Ai J, Zhou T, et al.* Transcatheter Arterial Embolization Alone for Giant Hepatic Hemangioma. *PLoS ONE* 2015; 10(8): e0135158.
  9. *Guglielmi A, Ruzzenente A, Conci S, Valdegamberi A, Iacono C.* How much remnant is enough in liver resection?. *Dig Surg* 2012; 29(1): 6–17.
  10. *Thakrar PD, Madoff DC.* Preoperative portal vein embolization: An approach to improve the safety of major hepatic resection. *Semin Roentgenol* 2011; 46(2): 142–53.
  11. *van den Broek MA, Olde DS, Dejong CH, Lang H, Malagó M, Jalan R, et al.* Liver failure after partial hepatic resection: Definition, pathophysiology, risk factors and treatment. *Liver Int* 2008; 28(6): 767–80.
  12. *Ribero D, Abdalla EK, Madoff DC, Donadon M, Loyer EM, Vauthey J.* Portal vein embolization before major hepatectomy and its effects on regeneration, resectability and outcome. *Br J Surg* 2007; 94(11): 1386–94.
  13. *Golriz M, Majlesara A, El Sakka S, Ashrafi M, Arwin J, Fard N, et al.* Small for Size and Flow (SFSF) syndrome: An alternative description for posthepatectomy liver failure. *Clin Res Hepatol Gastroenterol* 2016; 40(3): 267–75.
  14. *Vicente E, Quijano Y, Ielpo B, Duran H, Diaz E, Fabra I, et al.* Is "small for size syndrome" a relatively new complication after the ALPPS procedure? *Updates Surg* 2015; 67(3): 273–8.
  15. *Eshkenazy R, Dreznik Y, Labat E, Zakai BB, Zende A, Ariche A.* Small for size liver remnant following resection: Prevention and management. *Hepatobiliary Surg Nutr* 2014; 3(5): 303–12.

Received on July 21, 2017.

Revised on September 26, 2017.

Accepted on October 2, 2017.

Online First October, 2017.